

## RESCUE, HANDLING AND RELEASE OF A MELON-HEADED WHALE, *PEPONOCEPHALA ELECTRA*, STRANDED IN CEARÁ, NE BRAZIL

MONICA REGINA ALVES MOTTA<sup>1</sup> AND CRISTINE PEREIRA NEGRÃO SILVA<sup>1</sup>

The melon-headed whale, *Peponocephala electra* (Gray, 1846), is a small cetacean that can reach 280cm in total length and weigh between 160 to 275kg (Bryden *et al.*, 1977). It has an elongated body, with long and sharply pointed pectoral fins, and a tall and falcate dorsal fin (Hetzel and Lodi, 1993). The shape of the head is triangular. The body coloration is predominantly black with gray areas on the ventrum (Jefferson and Barros, 1997). The skin of both upper and lower lips is white (Nakajima and Nishiwaki, 1965).

Melon-headed whales have a worldwide distribution in tropical and subtropical seas, however little is known about the distribution of these animals in the Atlantic Ocean (Mullin and Jefferson, 1994). This species prefers offshore habitats (Perrin, 1976; Perryman *et al.*, 1994), living in pods of 100 to 500 animals, with a known maximum of about two thousands individuals (Jefferson *et al.*, 1993).

The first documented mass stranding of melon-headed whales in the South Atlantic Ocean occurred in Bahia state, Brazil (Lodi *et al.*, 1990). Subsequent records of this species along the Brazilian coast have been made for Fernando de Noronha Island (Hetzel and Lodi, 1993), and the states of Alagoas (Fragoso *et al.*, 1994), Espírito Santo (Gasparini and Sazima, 1996), Ceará (Alves Jr. *et al.*, 1996), Sergipe (Serra *et al.*, 2000) and Rio Grande do Norte (Medeiros, 2003).

Since 1994, AQUASIS<sup>2</sup> staff has been recording marine mammal strandings along the coast of Ceará state, carrying out rescue operations, treatment procedures, recovering carcasses and performing necropsies.

The objective of the present work is to discuss the most recent rescue and release of a specimen of melon-headed whale (*Peponocephala electra*) in Ceará state.

On 5<sup>th</sup> May 2003, around 6:00 a.m., a live female *Peponocephala electra* (REMANE # 02C1512) measuring 245cm in total length, stranded next to Canoa Quebrada beach (04°31'53.2" S, 37°40'16.7" W), Ceará state, northeastern Brazil (Figure 1).

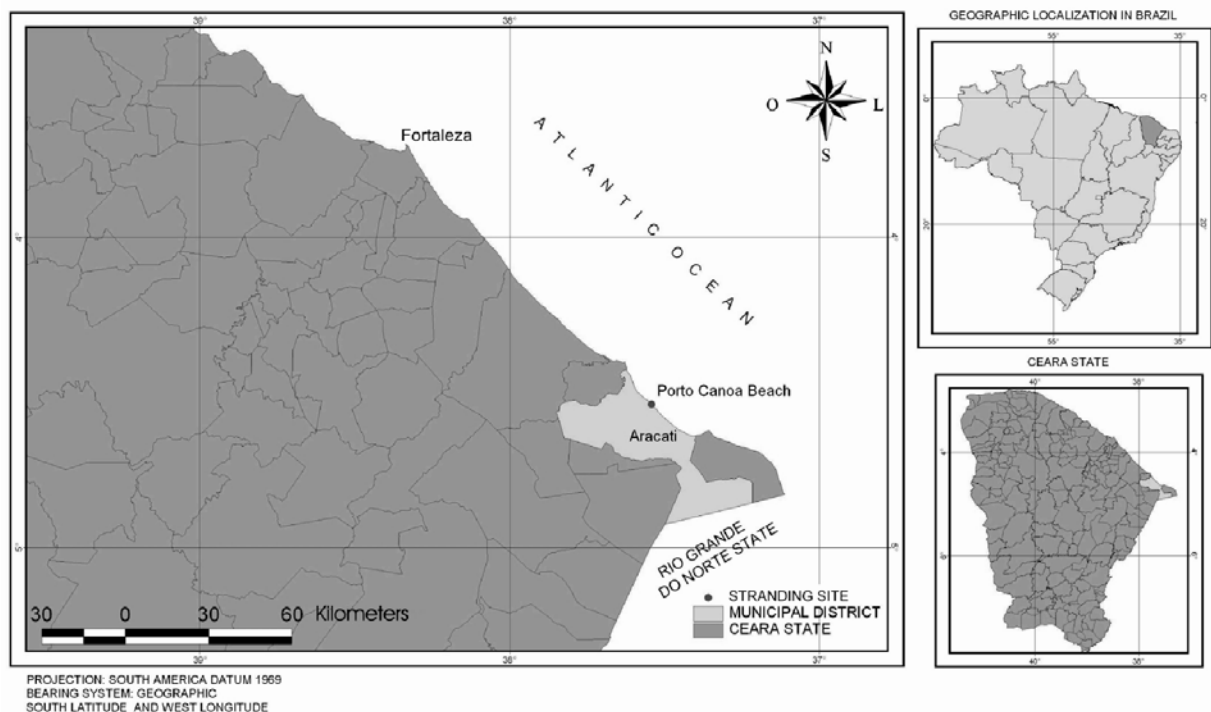


Figure 1. Stranding site of a melon-headed whale (*P.electra*) in Ceará state, northeastern Brazil.

<sup>1</sup>AQUASIS - Associação de Pesquisa e Preservação de Ecossistemas Aquáticos, Centro de Reabilitação de Mamíferos Marinhos. Praia de Iparana, s/n, SESC Iparana, 61600-000, Caucaia, Ceará, Brazil. E-mail: mottavet@uol.com.br.

<sup>2</sup>Associação de Pesquisa e Preservação de Ecossistemas Aquáticos, a non-profit organization, member of the Advisory Council of REMANE - Rede de Encalhes de Mamíferos Aquáticos do Nordeste (Brazilian Northeast Aquatic Mammal Stranding Network).

\*Corresponding author, e-mail: mottavet@uol.com.br.

After unsuccessful efforts by local residents to push the whale back into the water, the animal was placed in a 6m diameter artificial pool containing treated freshwater, located in a resort near the stranding site.

AQUASIS rescue team arrived on site at 2:30 p.m., three hours after receiving the first call. The whale did not present any resistance to the handling. Biometry, according to the Brazilian Action Plan for the Aquatic Mammals (IBAMA, 2001), and general health assessment procedures were conducted.

During clinical examinations, the whale was alert, with positive corneal reflex and good jaw tone. In the pool, the animal's behavior was restful, showing sporadic swimming movements and good flotation. There were no signs of bleeding or discharges from the mouth, blowhole, anal or genital openings.

The individual was thin, with superficial red lesions without scar borders spread over the body. Lung assessment indicated a discreet crackle on the left side. Respiratory and heart rates assessment showed a range from 3-4 b.p.m and 100-110 b.p.m, respectively. Blood samples were not collected due to the dehydrated state of the animal.

During the clinic assessment, the animal was treated with long-term antibiotics, vitamin complex and anti-inflammatory (Table 1). Considering the dehydrated state of the whale, the fact that it remained in the pool during at least five hours, could have induced it to drink freshwater, possibly helping to restore the salt and water balance, as suggested by Geraci and Lounsbury (1993).

After three hours of observation, considering the reasonable clinical condition of the animal, maturity and favorable oceanographic and logistic conditions, the AQUASIS team opted to release the animal. Scars and individual marks were photographed so that the animal could be recognized in case of restranding.

The release procedure was carried out with the assistance of a shrimp trawler-type motorboat. The animal was removed from the pool and taken to sea in a stretcher, and then lifted into the boat. The goal was to reach approximately 4km from the coast, according to the pelagic distribution of this species. However, during the trip, possibly due to the effects of the transport, the whale started to show signs of acute stress and shock, with mydriasis, negative corneal reflex and dorsal curving.

The whale had to be immediately released 1km from the coast. In the water, it showed a good swimming reflex with synchronized breaths. The animal was heading west, when it was sighted for the last time, swimming parallel to the coast.

Soon after release, monitoring from land began (at about 5:30 p.m.), and it ended past midnight. Forty-eight hours after releasing the animal, a new monitoring effort was carried out, with the assistance of the local Brazilian Environmental Agency (IBAMA). Fishermen and AQUASIS volunteers in coastal communities near the stranding site were contacted to report any information regarding the animal. No evidence of restranding was reported.

**Table 1.** Drugs used in the treatment of a melon-headed whale (*P. electra*) in Ceará state, northeastern Brazil.

DRUGS	DOSE	ADMINISTRATION	PURPOSES
<b>Pentabiótico Veterinário Pequeno Porte<sup>®1</sup></b>			
Benzathine Benzylpenicillin 600.000 IU	4 ml	M	Antibiotic
Procaine Benzylpenicillin 300.000 IU			
Potassic Benzylpenicillin 300.000 IU			
Diiestreptomicina Sulfato (base) 250mg			
Estreptomicina Sulfato (base) 250mg			
<b>Potenay Oral NF<sup>®1</sup></b>			
Mephentermine Sulfate 66.7mg	12 ml	O	Stimulant
Vitamin B2 14.0mg			
Vitamin B6 10.0mg			
Nicotinamida 140.0mg			
Calcium Glycerylphosphate 500.0mg			
Manganese Glycerylphosphate 50.0mg			
Potassium Glycerylphosphate 100.0mg			
Sodium Glycerylphosphate 1000.0mg q.s.p. 100.00ml			
<b>Omcilon -A Orobase<sup>®2</sup></b>			
Triancinoloma Acetonido 1mg/g	Fine layer	T	Anti-inflammatory

Drug Administration: (M) intramuscular; (O) oral; (T) topic.

<sup>1</sup>Fort Dodge Laboratory.

<sup>2</sup>Bristol-Myers Squib Brasil.

According to Bryden *et al.* (1977), *P. electra* females reach sexual maturity between 225 and 227cm of total length. In this case, with 245cm of total length, the animal was considered mature.

The apparent weight loss suggests a chronic pathologic process. The presence of a discreet disturbance in the lung may indicate a disease in this organ, possibly in the initial stage of development, which can probably be related to the cause of the stranding. The skin lesions were considered recent and are most likely associated with superficial damage due to the intertidal beach rocks present in the stranding area.

Needham (1993) cited a normal respiratory rate in a cetacean ranging from 1 to 4 breaths per minute, and Walsh *et al.* (1990) considered the heart rate to range from 60 to 100 beats per minute. In that sense, although the animal's breath rate ranged 3-4 b.p.m and heart rate ranged 100-110 b.p.m., those parameters were considered reasonably normal due to stranding stress.

According to Perryman *et al.* (1994), virtually nothing is known about pathology in melon-headed whales. Morimitsu *et al.* (1986) suggested tissue damage associated with parasitic infestation as a possible cause of mass strandings related to this species. AQUASIS registered five prior occurrences of *P. electra* in Ceará coast (Alves Jr. *et al.*, 1996; unpublished data), four of them alive, all single strandings. In two of these individuals it was possible to perform dissections of the air sinuses and tympanic cavities and both showed heavy parasitic infestation. However, it was impossible to establish how much this factor contributed to the strandings.

The decisions taken by the rescue team with a live stranded cetacean depend on the size, age and clinical state of the animal, in addition to the environmental conditions, time and logistics available in the area (Geraci and Lounsbury, 1993). Accurate assessment of a stranded cetacean's condition is a difficult undertaking. Each stranding must be treated as a unique event with an evaluation of all the available information.

According to Mayer (1996), pelagic species of cetaceans may not adapt well to the stress of captivity and so rehabilitation may inevitably be less successful. Ground transportation is stressful for cetaceans and could only serve a limited distance, as it may cause muscular stiffness, inappetence, anaemia, pressure necrosis and respiratory problems (Joseph *et al.*, 1990).

In this case, if the specimen had been promptly removed from the stranding area to the AQUASIS Marine Mammal Rehabilitation Center, it would have taken over 2.5hr. How long a debilitated animal can tolerate even the best quality transportation is not easily estimated, since emergency clinical examinations performed in the field usually rely on physical characteristics that cannot accurately measure stress levels, as would lab exams (e.g., blood samples). In any case, journeys over 2-3 hours need careful justification, since prolonged handling all add to the stress an animal experiences.

Another factor taken into consideration is that the AQUASIS Rehabilitation Center was designed for newborn and juvenile manatees, and the size of the pools is not adequate for pelagic cetaceans, which are much more active than manatees. Kang (1980) described melon-headed whales as nervous and "flighty" in captivity. In the stranding of this *P. electra* individual it was concluded that the immediate treatment and release would probably give the cetacean its best chance of survival as it limited the degree of stress to which the animal would be exposed.

Mayer (1996) stated that very little information exists about the success in rehabilitation or otherwise of treatment of live stranded cetaceans, especially concerning long term survival, which makes critical evaluation of options a difficult task.

In this particular case, we considered the procedure adopted by the rescue team the most adequate alternative due to the conditions explained above, and mainly due to the lack of proper cetacean rehabilitation facilities in Brazil. However, since most stranding situations are complex (Geraci and Lounsbury, 1993), each stranding has to be dealt carefully considering the clinical condition of the animal, and the resources available, especially concerning logistics and rehabilitation facilities.

Rescue and rehabilitation of cetaceans along the Brazilian coast are still poorly documented, resulting in few published data that serve as a base for medical care of these animals. All data collected during these occasions are extremely important to improve the knowledge on cetacean strandings and treatment, especially those classified by the IUCN (2003) as "data deficient".

### Acknowledgements

The authors would like to thank the AQUASIS' rescue team (Alexandra Fernandes Costa and Juaci Araújo de Oliveira) for the efforts spent on the beach; the Brazilian Environmental Agency (IBAMA) and the Centro Mamíferos Aquáticos - CMA, to provide the team transportation to the stranding site; to Miss Giovana Maraschin and Miss Márcia Elisa Pereira, who helped with the draft English version; Guilherme Marques de Souza who kindly provided the map; Mr. Alberto Alves Campos for his comments and suggestions; and Drs Nélio Barros and Charles Manire, for the valuable comments on the original manuscript.

### References

- ALVES JR., T.T., ÁVILA, F.J.C., OLIVEIRA, J.A., FURTADO NETO, M.A.A., AND MONTEIRO NETO, C. (1996) Registros de cetáceos para o litoral do estado do Ceará, Brasil. *Arquivo de Ciências do Mar* 30 (1-2): 79-92.
- BRYDEN, M.M., DAWBIN, W.H., HEINSOHN, G.E., AND BROWN, D.H. (1977) Melon-headed whale, *Peponocephala electra*, on the east coast of Australia. *Journal of Mammalogy* 58 (2): 180-187.

- CORDES, D.O. (1982) The causes of whale strandings. *New Zealand Veterinary Journal* 30:21-24.
- FRAGOSO, A.B.L., DORNELES, P.R., LIMA, R.P., CASTRO, D.F., AND BRITO JR, J.L. (1994) *Registros do golfinho clymene, Stenella clymene, e do golfinho cabeça-de-melão, Peponocephala electra, para o litoral de Alagoas, Brasil.* Pages 133-134 in Abstracts, 6<sup>o</sup> Reunião de Trabalho de Especialistas em Mamíferos Aquáticos da América do Sul, 24 -28 October 1994, Florianópolis, Brazil.
- GASPARINI, J.L. AND SAZIMA, I.A. (1996) A stranded melonheaded whale, *Peponocephala electra*, in southeastern Brazil, with comments on wounds from the cookiecutter shark, *Isistius brasiliensis*. *Marine Mammal Science* 12: 308-312.
- GERACI, J.R. AND LOUNSBURY, V.J. (1993) *Marine mammals ashore - A field guide for strandings.* Texas A & M Sea Grant Publication. Galveston, Texas.
- HETZEL, B. AND LODI, L. (1993) *Baleias, botos e golfinhos: Guia de identificação para o Brasil.* Editora Nova Fronteira. Rio de Janeiro, Brazil.
- IBAMA (2001) *Mamíferos aquáticos do Brasil: Plano de ação II.* Instituto Brasileiro de Meio Ambiente e Recursos Naturais Renováveis, Brazil.
- IUCN (2003) *2003 IUCN Red list of threatened species.* Available at: <<http://www.redlist.org>>. Accessed on 23 September 2004.
- JEFFERSON, T.A. AND BARROS, N.B. (1997) *Peponocephala electra.* *Mammalian Species.* 553: 1-6.
- JEFFERSON, T.A., LEATHERWOOD, S. AND WEBBER, M.A. (1993) *Marine mammals of the world.* Rome, FAO.
- JOSEPH, B.E., ASPER, E.D., ANTRIM, J.F. AND PEARSON, J.C. (1990) Marine mammal transport Pages 543-552 in DIERAUF, L.A. (Ed) *CRC Handbook of Marine Mammal Medicine Health, Disease and Rehabilitation.* Boca Raton, CRC Press, L.A.
- KANG, I. (1980) Care and training of two melon-headed whales (*Peponocephala electra*). Pages 15-18 in MURCHISON, A.E. (Ed) *Proceedings of the International Marine Animals Trainers Association Conference.* International Marine Animals Trainer's Association, Kailua, Hawaii.
- LODI, L., SICILIANO, S. AND CAPISTRANO, L. (1990) Mass stranding of *Peponocephala electra* (Cetacea, Globicephalinae) on Piracanga beach, Bahia, Northeastern Brazil. *Scientific Reports of Cetacean Research* 1: 79-84.
- MAYER, S. (1996) *A review of live strandings of cetaceans: Implications for their veterinary care, rescue and rehabilitation in the UK.* Whale and Dolphin Conservation Society, UK.
- MEDEIROS, P.I.A.P. (2003) *Registro de cetáceos encalhados no período de 1984 a 2003 no litoral do Rio Grande do Norte.* BSc. Thesis, Universidade Federal do Rio Grande do Norte. Natal, RN, Brazil.
- MORIMITSU, T., NAGAI, T., IDE, M., ISHII, A. AND KOONO, M. (1986) Parasitogenic octavus neuropathy as a cause of mass strandings of Odontoceti. *Journal of Parasitology* 72: 469-472.
- MULLIN, K.D. AND JEFFERSON, T.A. (1994) First sightings of melon-headed whales (*Peponocephala electra*) in the Gulf of Mexico. *Marine Mammal Science* 10 (3): 342-348.
- NAKAJIMA, M. AND NISHIWAKI, M. (1965) The first occurrence of a porpoise (*Electra electra*) in Japan. *Scientific Reports of the Whales Research Institute* 19: 91-104.
- NEEDHAM, D.J. (1993) Cetacean strandings. Pages 415-425 in FOWLER, M.E. (Ed) *Zoo & Wild Animal Medicine - Current Therapy* 3. W.B. Saunders Company, Philadelphia.
- PERRIN, W.F. (1976) First record of the melon-headed whale, *Peponocephala electra*, in the eastern Pacific, with a summary of world distribution. *Fishery Bulletin* 74: 457-458.
- PERRYMAN, W.L., LEATHERWOOD, D.W.K. AND JEFFERSON, T.A. (1994) Melon-headed whale *Peponocephala electra* Gray, 1846. Pages 363-368 in RIDGWAY, S.H. AND HARRISON, R. (Eds) *Handbook of Marine Mammals. Vol.5. The first book of dolphins.* Academic Press, San Diego, California.
- SERRA, S.D., HUBNER, A. AND DÓREA-REIS, L.W.D. (2000) *Registro de mamíferos marinhos no litoral do estado de Sergipe.* Page 129 in Abstracts, 9<sup>a</sup> Reunião de Trabalho de Especialistas em Mamíferos Aquáticos da América do Sul, 30 October - 03 November 2000, Buenos Aires, Argentina.
- WALSH, M.T., ODELL D.K., YOUNG, G., ASPER E.D. AND BOSSART, G. (1990) Mass strandings of cetaceans. Pages 673-684 in DIERAUF, L.A. (Ed) *CRC Handbook of Marine Mammal Medicine Health, Disease and Rehabilitation.* CRC Press. Boca Raton, Florida.

Received 26 October 2004. Accepted 29 October 2005.